

Autoerotic deaths: report of two unusual cases

Ivana Kumičková¹, Mária Putško¹, Lubomír Straka¹, Martin Janík¹, František Štuller², František Novomeský¹, Jozef Krajčovič¹

¹ Institute of Forensic Medicine and Medicolegal Expertises, Jessenius Faculty of Medicine, Comenius University in Bratislava, Martin, Slovak republic

² Department of Forensic Medicine, Health Care Surveillance Authority, Martin, Slovak republic

SUMMARY

Autoerotic death is a rare but recurring phenomenon in forensic medicine. This article presents two cases of unusual autoerotic death with signs of autoerotic asphyxia. Although the first case appeared to be asphyxia, the autopsy confirmed natural cause of death during solitary sexual activity of 69-year-old man found with exposed and bandaged genitals. The other case was asphyxiation utilizing a plastic bag and multiple panties wrapped around the head of 18-year-old man disguised in women's dress.

Keywords: autoerotic asphyxia – autoerotic death – paraphilia – asphyxiophilia – suicide – sudden natural death

Úmrtí při autoerotice: popis dvou neobvyklých případů

SÚHRN

Autoerotická smrt je v soudním lékařství zriedkavým, ale opakujúcim sa javom. Zníženie prívodu kyslíka do tela spôsobuje pocity slabosti, stratu koncentrácie aj zvýšenie sexuálnej citlivosti. Pri neštandardných sexuálnych praktikách, autoerotickej asfyxiophilii, môže dôjsť ku nešťastnej náhode a smrti jedinca. Autoerotická smrt' býva najčastejšie spôsobená udusením obesením alebo uškrtením. Poklesom prívodu kyslíka do mozgu nastupuje bezvedomie, ktoré privodí zlyhanie tzv. „únikového“ mechanizmu s nástupom hypoxického poškodenia mozgu. V zriedkavých prípadoch nie je smrt' spôsobená asfyxiou, ale prirodzenou príčinou. Najčastejším podkladom je ochorenie srdcovo-cievneho systému. Tento článok predstavuje dva prípady nezvyčajnej autoerotickej smrti s charakteristickými znakmi autoerotickej asfyxie. Jedným z prípadov bola prirodzená smrt' 69-ročného muža pri osamotenej sexuálnej aktivite s odhalenými a obviazanými genitáliami. Druhým prípadom bolo zadusenie 18-ročného muža pomocou plastového vrečka omotaného okolo hlavy, ktorý bol prezlečený v dámskych šatách. V oboch prípadoch sa vyskytli znaky autoerotickej aktivity. Aj keď sa prvý prípad javil ako asfyxia, pitva potvrdila prirodzenú príčinu smrti. Smrt' spôsobila ruptúra steny ľavej komory srdca s následnou tamponádou perikardiálnej dutiny. Nízka incidencia prípadov autoerotickej smrti spolu s často nezvyčajnou situáciou na mieste nálezu tela môžu viesť k pochybnostiam a zámene za samovraždu alebo vraždu. Podrobná prehliadka miesta nálezu spolu s dokumentáciou pomáha k vylúčeniu cudzieho zavinenia a k správne mu určení príčiny smrti.

Kľúčové slová: autoerotická asfyxia – autoerotická smrt' – parafília – asfyxiophilia – samovražda – náhla prirodzená smrt'

Soud Lek 2020; 65(4): 84–87

Death caused by autoerotic activity is an accidental death that occurs during an individual's, usually solitary, sexual activity (1). The principle of autoerotic asphyxia is to reduce the supply of oxygen to the body and thus increase sexual gratification. The pathophysiological mechanism consists of a very early functional disorder of the inhibitory mechanisms of the limbic system and hippocampal formation, which leads to the activation of sexual arousal, euphoria and, in some individuals, sexual hallucinations (2,3,4). Common methods employed to ensure hypoxia include neck compression by suspension ligatures, use of a face mask, plastic bag or face mask placed over the head, occlusion of the nose and mouth by rubber masks, tape, plastic balls or plastic sheeting. Amongst less usual possibilities is chest compression, inhalation of deoxygenated volatiles or anesthetic volatiles (anesthesiophilia). Atypical methods of providing

increased sexual arousal are the use of electric current through wires and clamps serving as electrodes to areas of the genitals or erogenous areas (electrophilia). Death can be caused by the insertion of a foreign body – e.g. a vibrator – into the oral cavity and respiratory tract, that can lead to suffocation (1,2,3,5). In rare cases, the cause of death is natural, as presented in our first case. The first case describes a 69-year-old man with autoerotic choking activities coupled with genital bandaging. This autoerotic behaviour most likely led to increased demands of cardiovascular system culminating in acute myocardial infarction with postinfarction rupture of the left ventricular free wall. The second case describes an 18-year-old man who was found dressed in women's clothing with plastic bag and several panties placed over the head. This case shows typical signs of transvestitism in combination with autoerotic asphyxiophilia.

✉ Correspondence address:

Lubomír Straka, MD, PhD, Assoc Prof
Institute of Forensic Medicine and Medicolegal Expertises, Jessenius Faculty of Medicine, Comenius University in Bratislava
Kollárova 10, 036 01 Martin, Slovak republic
phone: +421 434 132 770
fax: +421 434 132 770
e-mail: lubomir.straka@uniba.sk

Received: June 25, 2020

Accepted: July 24, 2020

CASE REPORTS

Case 1

A body of 69-year-old man was found death at his home address. The body was lying face down with exposed genitalia which were tightly bandaged by rubber bands and shoe laces (Figure 1A,B). The man was dressed in kiss-patterned boxers. A lubricated vibrator densely covered with silicone lubricant was found in the close vicinity of the body. Additionally, there was plenty of various pornographic material found at the scene. At autopsy, a lubricant-like substance was found within upper airways, predominantly

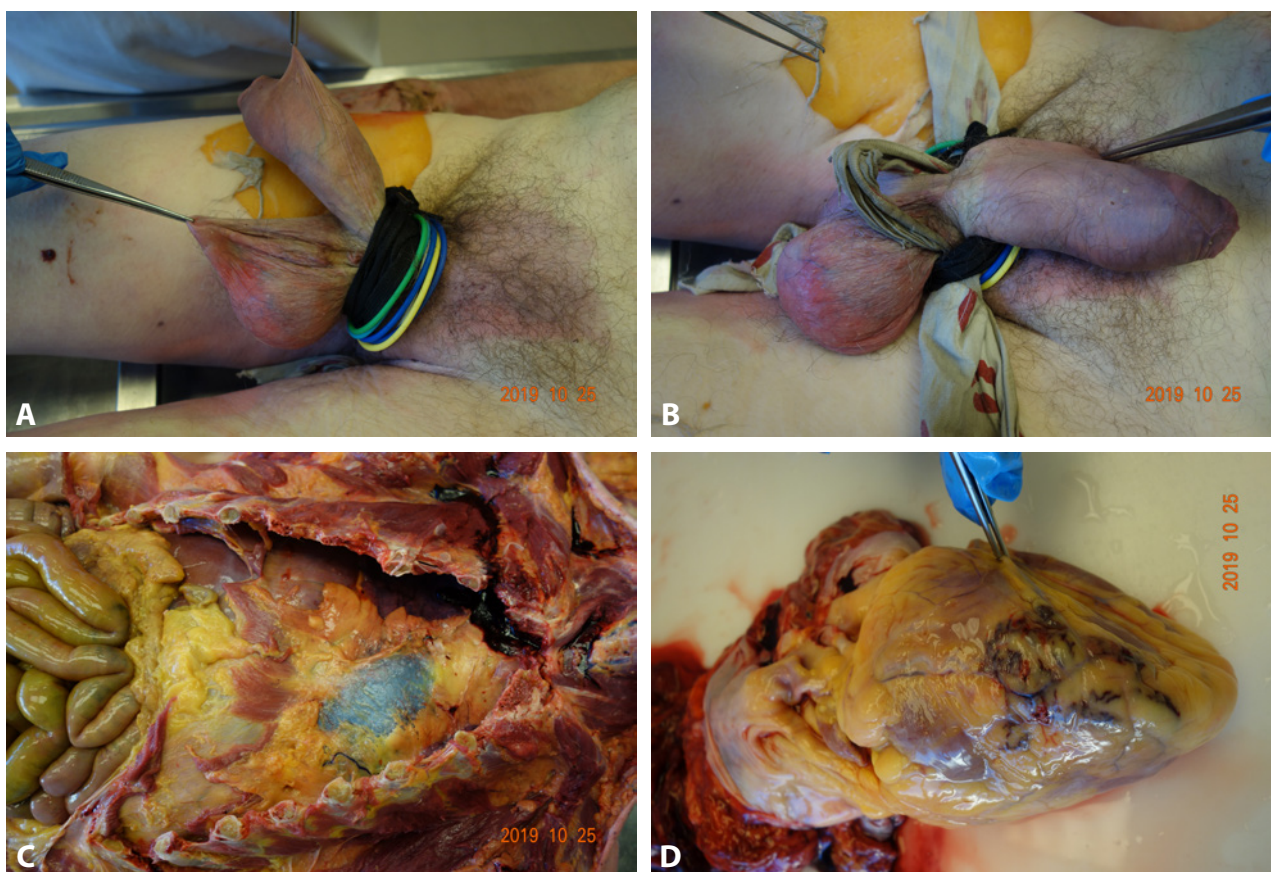


Fig. 1. The autopsy findings of 69-year-old man. **A:** Tightly bandaged genitalia. **B:** Genitalia bandaged by rubber bands and shoe laces. **C:** Visible blood in the pericardial cavity (asterisk). **D:** The small tear of left ventricular free wall (arrow).

covering the larynx and the trachea. There was extensive mucosal bleeding of the trachea and the larynx. The most significant finding was disclosed at autopsy of the heart. Upon the opening of the pericardium, 350 ml of coagulated blood was found in the pericardial cavity (Figure 1C). In the area of left ventricular free wall, bleeding and a small tear through which blood seeped was observed (Figure 1D). Cross sections of heart muscle showed a macroscopically visible ischemic sidewall deposit along with muscle rupture. Histology supported the autopsy findings. A coagulation necrosis was fully developed with loss of nuclear staining and widespread neutrophil infiltration. The assumption of insufficient blood supply to the myocardial muscle was furthermore supported by finding rigid and calcified plaques stretched on the lining of the coronary arteries. Toxicological reports showed no presence of foreign substances. The cause of death was resolved as a cardiac tamponade secondary to postinfarction myocardial rupture.

Case 2

A dead body was found lying on the ground on a carpet in a family house. Clothing suggested young, tall and slim-figured woman. A plastic bag wrapped around the head of the deceased with 2 cm wide pink duct tape made it impossible to do further identification (Figure 2A, B). Tape, identical to the material used to sew woman underwear, was wrapped around the neck three times and its loose end – 170 cm long – was laid out next to the body. Deceased was wearing tights, short blouse and a woman's two-piece suit. Another pair of tights were also put on both upper limbs (Figure 2C). After pulling off some layers of clothing, forensic pathologist present at the scene discovered that it was a body of a young man wearing four panties and three bras. Removing the plastic bag from the head showed five panties stretched over his head. Leg parts of the tights were wrapped around head and his half-open mouth



Fig. 2. The body scene of 18-year-old young man. **A:** Position of the deceased at the death scene. **B:** A plastic bag wrapped around the head of the deceased with a tape. **C:** The young man dressed in women's clothing.

and vertically over the top of the head and under his chin. In mouth area, they were wet from saliva foam and vomit. Once all objects were removed from the head, the deceased was identified as the 18-year-old son of the house owners. Autopsy showed that only one testicle was present in his scrotum, the other one was surgically removed when he was 13 years old. The deceased was a somatically well-developed young man. Toxicology did not confirm any presence of alcohol or other forensically important substances. On panties worn by the deceased, ejaculate was confirmed both microscopically and biochemically. The way the duct tape and tights were wrapped around his throat excluded another person's involvement. The cause of death was affirmed as asphyxiation by external airway obstruction by a plastic bag.

DISCUSSION

Typical for an autoerotic death is the presence of a dead body of a young man, most often aged 15-25, Caucasian race, in a safe and locked area with signs of previous masturbation. Majority of reported cases come from western countries. Sauvageau and Vernon describe that only 4 % of victims are non-Caucasian. Of the non-Caucasian 50 % are Negroid race and 36 % Asians (9,12).

In the first case, there was a 69-year old man locked in his apartment with evidence of previous erotic activity. The age of deceased was not ordinary. Elderly victims of more than 65 years are sporadic, consisting of less than 1 % of cases. Since increasing age is linked with higher morbidity, natural death associated with autoerotic activity ("la morte d'amour") most often affects men over the age of 50 (5,9,12). Occurrence of autoerotic death cases caused by natural disease is infrequent. Majority of the natural causes of death during autoerotic activity in older men are of cardiovascular causes (5,6). Also in the first case report, decreased oxygen supply to the heart muscle resulted in extensive previous myocardial infarction that was confirmed histologically. As mentioned earlier, coagulation necrosis was fully developed with loss of nuclear staining and widespread neutrophil infiltration. This condition is in literature described to be present after 48 to 72 hours after ischemia. The rupture of a myocardial wall may appear during the first 7 to 10 days after onset which corresponds to this case (13,14). Reduction of oxygen supply could be probably due to increased exertion during masturbation and suffocation during previous days. Further repetition of this autoerotic activity led to rupture of the necrotic myocardium. The whole process resulted in abrupt development of hemopericardium. Interesting is also the finding of bandaged genitals. Excessive stimulation of autonomic nervous system could have another negative effect on function of the heart muscle. According to Byard, deaths occurred from underlying organic illness such as cardiovascular disease should not be included within group of autoerotic deaths because it is not accidental (9). However, this opinion is still disputable (15).

On the other side is the case of a young, 18-year old man. The higher occurrence of autoerotic asphyxia in younger individuals can be explained by lust for new experience, lack of sexual contact with others, or to increase sexual excitement (9,16). In this case also his handicap should be considered – the loss of a testicle in the childhood – and the influence of this event on his psychosexual development. The orchiectomy could cause feelings of uneasiness, or shame about his body, especially in his young age. Low testosterone levels after loss of testicle can lead to anxiety (18). The primary purpose of cross-dressing

could be sexual, but another possibility was to prevent and release anxiety (10,17). The cause of death was asphyxiation by using a plastic bag wrapped around the head with consequent aspiration of agonal vomit. There could be a question if younger individual's autoerotic death is mainly violent and older ones are associated with natural death. According to Lohner et al. it is impossible to draw any conclusion on the manner of death solely regarding the age of the decedent. Autoerotic accidents also occur to older people as well as young adults (8).

Personal features of the young man helped him to hide his difference in psychosexual development from his family and other people. Autoerotic asphyxiophilia is an intimate activity that most of the family is unaware of. After finding the body, family members often change the scene and cover traces that would lead to a correct diagnosis. On many occasions, they prefer to accept the fact that the deceased committed a suicide. They fear about stigmatizing the family and damaging the "good name" of the deceased (7). In both cases was the finding place intact which gave an opportunity reliably to determine the circumstances of death. Although in the second case was the victims' identification initially different due to the cross-dressing of the deceased. Coincidence with transvestitism is common and the body disguised in women's clothing can be misidentified (9,10). Accidental deaths caused by autoerotic asphyxia are rare in forensic medicine practice, thus incorrect manner of death can be assessed at the scene. Autoerotic death can be frequently misplaced for suicide or murder (5). Throughout these two case reports, authors would like to draw attention to the importance of not only proper body examination but also proper inspection and documentation of the surroundings in which the body was found. Body scene itself is often peculiar and it is rather difficult to exclude another person's involvement. Thorough body examination and possible interview with witnesses or bereaved can be invaluable in further investigation (8,11).

The most common method of inducing hypoxia is compression of the neck, chest or abdomen. Death occurs when an individual falls unconscious and loses control of the "escape" mechanism. The escape mechanism is a security system that protects a person from suffocation (1,6). In literature, escape mechanism is described to be present in most cases, but in practice the mechanism is usually not found, similar to the mentioned cases. Lohner et al explain that it could be due to a low level of risk awareness and that constructing such mechanism can be complicated (8). Furthermore, absence of escape mechanism does not indicate suicide.

However, it should be added, not only adults practice this dangerous activity. Among children is widespread a dangerous game called a "Choking game". The essence is to reduce the supply of oxygen to the brain and the consequent feeling of euphoria and relaxation, without the use of illegal drugs. The intention of increasing sexual sensitivity and arousal is not present (19).

In regards of toxicological analysis, alcohol is rarely present. Amongst the most used drugs in developed countries are cocaine, MDMA (ecstasy) and various substances that increase sexual motivation (e.g. "poppers"). Older men, in order to achieve higher sexual potency, use various medical drugs. For example, sildenafil is contraindicated in patients taking any long-acting nitrates or using short-acting nitrates because of the risk of developing potentially life-threatening hypotension and patients with severe cardiac conditions (8,12,20). Despite negative toxicological analysis in our presented cases, toxicological analysis should be always performed.

CONCLUSION

Autoerotic death is defined as accidental death occurring during individual sexual activity, in which the mechanism for ensuring increased sexual sensitivity fails and causes death. The most common mechanism is hanging or strangulation resulting in suffocation (6). Sometimes the circumstances surrounding the death of an individual can be obvious, sometimes they can be destroyed by family of the deceased, but the fact remains that the correct approach to the body examination is crucial for

identifying and correctly describing the manner of death. Toxicological analysis plays also an important role in determination of cause of death. In the case reports discussed in the article, authors tried to point out remarkable facts about the death caused by autoerotic asphyxia and the approach to proper diagnostics and forensic analysis.

CONFLICT OF INTEREST

The authors declare that there is no conflict of interest regarding the publication of this paper.

REFERENCES

1. **Schellenberg M, Racette S, Sauvageau A.** Complex Autoerotic Death with Full Body Wrapping in a Plastic Body Bag. *J Forensic Sci* 2007; 52(4): 954.
2. **Saukko P, Knight B.** *Knight's Forensic Pathology* (4th ed). Boca Raton: CRC Press, 2016.
3. **Seidl S.** Accidental autoerotic death. *Forensic Pathology Reviews* 1: 235-262.
4. **Janssen W, Koops E, Anders S, Kuhn S, Püschel K.** Forensic aspects of 40 accidental autoerotic deaths in Northern Germany. *Forensic Science International* 2005; 147S: S61-S64.
5. **Dettmeyer RB, Verhoff A, Schütz HF.** *Forensic Medicine: Fundamentals and Perspectives* Berlin: Springer, 2014.
6. **Baber Y, Bott E.** Natural death in the setting of autoerotic practice. *Forensic Sci Med Pathol* 2016; 12: 174-177.
7. **Byard, RW.** Manner of death associated with autoerotic practice. *Forensic Sci Med Pathol* 2016; 12: 236-237.
8. **Lohner L, Sperhake JP, Schröder KAS.** Autoerotic Deaths in Hamburg, Germany: Autoerotic accident or death from internal cause in an autoerotic setting? A retrospective study from 2004-2018. *Forensic Science International* 2020; Journal Pre-proof. Accessed on 18th of May.
9. **Byard RW.** Autoerotic death: a rare but recurrent entity. *Forensic Sci Med Pathol* 2012; 8: 349-350.
10. **Weiss P.** *Sexuální deviace*. Praha: Portál, 2008.
11. **Dickerson EM, Jones P, Wilkins D, Regnier J, Prahlow JA.** Complicated suicide versus autoeroticism. A case involving multiple drugs and porta-potty. *Am J Forensic Med Pathol* 2013; 34: 29-33.
12. **Sauvageau A, Geberth VJ.** Elderly victim: an unusual autoerotic fatality involving an 87-year-old male. *Forensic Sci Med Pathol* 2009; 5: 233-235.
13. **Mohan H.** *Patológia*. Bratislava: Balneotherma, 2011.
14. **Buja LM, Krueger GRF.** *Netter's Illustrated Human Pathology (Updated edition)* Philadelphia: Elsevier, 2014.
15. **Sauvageau A.** Current Reports on Autoerotic Deaths—Five Persistent Myths. *Curr Psychiatry Rep* 2014; 16: 430.
16. **Breitmeier D, Mansouri F, Albrech K et al.** Accidental autoerotic deaths between 1978 and 1997 Institute of Legal Medicine, Medical School Hannover. *Forensic Science International* 2003; 137: 41-44.
17. **Skoogh J, Steineck G, Cavallin-Stahl E et al.** Feelings of loss and uneasiness or shame after removal of a testicle by orchidectomy: a population-based long-term follow-up of testicular cancer survivors. *International Journal of Andrology* 2010; 34: 183-192.
18. **Aydogan U, Aydogdu A, Akbulut H et al.** Increased frequency of anxiety, depression, quality of life and sexual life in young hypogonadotropic hypogonadal males and impacts of testosterone replacement therapy on these conditions. *Endocrine Journal* 2012; 59(12): 1099-1105.
19. **Egge MK, Berkowitz CD, Toms C, Sathyavagiswaran L.** The Choking Game: A Cause of Unintentional Strangulation. *Pediatric Emergency Care* 2010; 26(3): 206-208.
20. **Pasha HCH.** Sildenafil (Viagra) and the heart. *J of Family and Community Medicine* 2001; 8(2): 63-66.