

Crime scene investigation and dynamic reconstruction: importance of synergic collaboration between forensic pathology and digital reconstruction for work-related fatalities

Alessandro Feola¹, Giulio Di Mizio², Francesco La Sala¹, Carmela Giordano¹, Bruno Della Pietra¹

¹ Department of Experimental Medicine, University of Campania "Luigi Vanvitelli", Naples, Italy.

² Department of Law, Section of Forensic Medicine, University of Magna Graecia, Catanzaro, Italy.

SUMMARY

A crime scene is the result of the dynamic interrelation of various factors. Where a fatality is involved, thorough analysis of the scene by a forensic pathologist produces the first data for verifying consistency between the necropsy results and witness testimonies toward defining the dynamics of injury and death. This step is extremely important in identifying any liability. We present the case of a construction worker who fell through a trapdoor between two floors while holding an iron beam at a building site. This case demonstrates the effectiveness of an integrated approach, using both classic forensic investigation techniques and digital 3-D reconstruction: it allowed verification of the dynamics of the injury and provided important information in assessing the employer's liability.

Keywords: crime scene investigation – autopsy – digital 3D reconstruction

Místo činu a digitální rekonstrukce: využití digitálních rekonstrukcí v soudním lékařství v případě smrtelných pracovních úrazů

SOUHRN

Místo činu je výsledkem dynamického působení vzájemně se ovlivňujících faktorů. Pečlivá analýza místa úmrtí soudním lékařem poskytuje prvotní informace pro ověření souladu mezi pitvěním nálezem a výpověďmi svědků a pro stanovení mechanismu úrazu a úmrtí. Tento krok je nesmírně důležitý pro stanovení odpovědnosti za úraz. Prezentujeme případ stavebního dělníka, který propadl dveřmi mezi dvěma patry na staveništi, zatímco držel železný nosník. Tento případ demonstruje efektivitu komplexního přístupu zahrnujícího jak klasické forenzní vyšetřovací metody, tak metody digitální 3D rekonstrukce. Tento přístup nám umožnil ověřit dynamiku úrazu a poskytnul nám důležité informace pro posuzování odpovědnosti zaměstnavatele.

Klíčová slova: ohledání místa činu – pitva – digitální 3D rekonstrukce

Soud Lek 2021; 66(1): 2–5

A crime scene is the result of the dynamic interrelation of various factors. Where a fatality is involved, evidence found at the scene includes the corpse and traces (biological and non-biological) present on it as well as the results of the interaction with the environment before, during, and after the incident (1,2). Thorough analysis of the scene and timely interviewing witnesses require an immediate assessment regarding congruence with technical data: as part of the autopsy investigation, they support a definitive verification of the injury and dynamics of the lethal event. This point is critical when establishing employers' liability in the case of occupational fatalities. On-site corpse inspection by a forensic pathologist is a mandatory part of the crime scene investigation: it may provide important information

for subsequent stages of the investigation. However, in some cases, medicolegal experts are not present at the scene, leading to loss or dispersion of important evidence (3). We present here the case of a construction worker who was found dead at a building site after falling through a trapdoor used for conveying industrial installation equipment. This case demonstrates that an integrated approach, involving both classic forensic investigation techniques and 3-D reconstruction, allowed verification of the dynamics of the injury and lethal event.

CASE REPORT

A construction worker at an industrial building site had been directed by another company employee to carry an iron beam, which was 36 kg in weight and 100 cm in length, from the first floor to the second floor. After a short time, the second worker, who was on the first floor, heard a loud noise: it sounded as if something had fallen from above. He went to another part of the first floor, where he found his coworker lying prone in a pool of blood: the first worker was at the base of metal tube scaffolding, which extended from the first to the second floor. The second worker realized that his workmate had fallen through a rectangular trapdoor (50 cm x 150 cm), which

✉ Correspondence address:

Dr. Alessandro Feola

Department of Experimental Medicine

University of Campania "Luigi Vanvitelli"

via Luciano Armanni 5 - 80138 Naples, Italy

e-mail: alessandro.feola@icloud.com

Received: June 5, 2020

Accepted: September 24, 2020

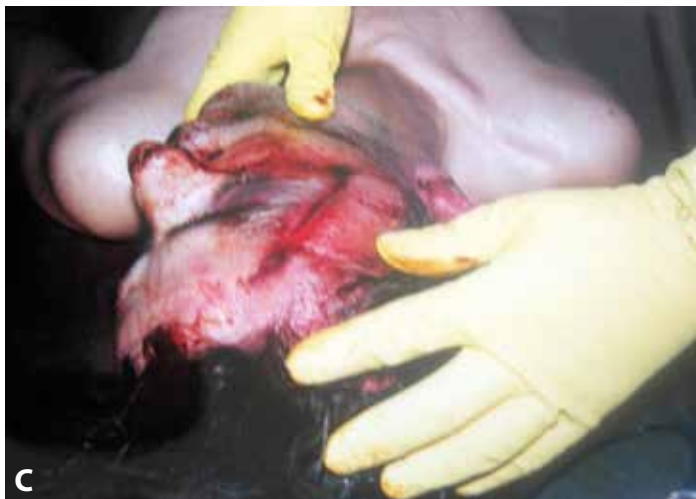

Figure 1. A, B, D: building where the accident took place. **C:** linear laceration involving the skin and subcutaneous tissues, 8 cm long, in the right frontal-zygomatic region.

was sufficiently wide to allow equipment to be transferred between the floors. Some wooden planks had also fallen together with the worker. No one heard the first worker crying out as he fell (Figure 1A, B, D).

A judicial inquiry was initiated to assess the cause of death and the employer's liability. The corpse was 166 cm in length and 75 kg in weight. During the autopsy, the following lesions were found: (a) a linear laceration involving the skin and subcutaneous tissues, 8 cm long, in the right frontal-zygomatic region, with a cranio-caudal course inscribed within a wider ecchymotic area, which included the latero-orbital region and expanded toward the ipsilateral temporal region (Figure 1C); (b) thick fractures at the parietal and right temporal squamosa, extending to a larger fracture in the anterior cranial fossa and right middle cranial fossa, where traumatic decay of the right petrous ridge and mastoid was evident; (c) deep abrasion, with an almost ellipsoidal shape, to the right patellar lateral surface and two ecchymotic areas at the level of the distal third of the thigh and of

the proximal third of the right leg, corresponding to anterolateral and anteromedial surfaces.

DISCUSSION

Fatal occupational injuries are an important social problem. Industrial construction sites are among the most dangerous workplaces (4,5). The mechanisms of injury and trauma characteristics are crucial in regulatory investigations into the cause of accidents: they have evidentiary value in legal proceedings. It is necessary to evaluate whether the injuries are consistent with the events surrounding the accident and how they appear to the investigator: they help corroborate or disprove witness statements (1).

Digital rendering using 3-D reconstruction of the findings at the scene of an accident can provide clear evidence about the dynamics of the injury (6,7). With the case presented here, it

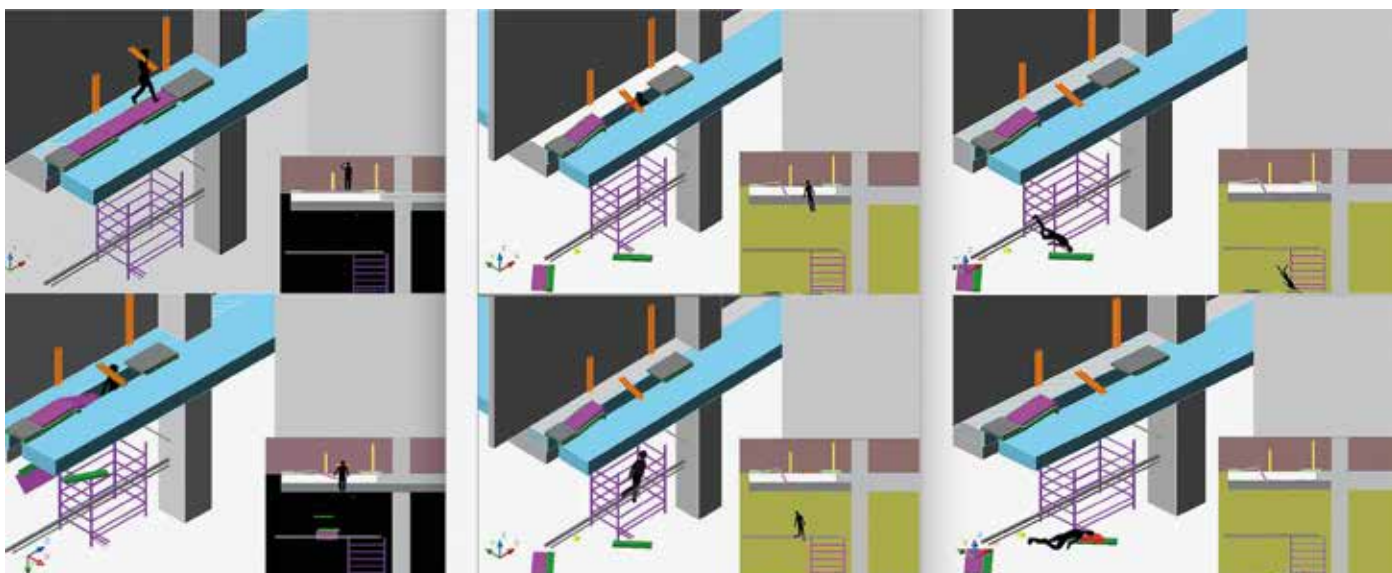


Figure 2. Reconstruction of the fatal event.

was initially supposed that the worker had fallen with his head downward. However, that scenario did not explain the severe trauma of the right middle cranial fossa; above all, it did not account for the worker falling silently and not later shouting for help. That reconstruction did not fully explain the position of the iron beam across the trapdoor. The technical data obtained were examined using a reconstruction of the dynamics of injury by means of digital rendering (Figure 2). In that way, the event could be divided into four different phases.

1. In the first phase, the worker carried an iron beam to the second floor of the building. That beam was to be placed together with others against the wall behind the trapdoor. The worker was facing the wall, and he placed his feet on the trapdoor, which was initially able to support his weight. He lifted one of the iron beams and set it on his right shoulder; he then turned to face away from the wall. In that position, the beam was positioned obliquely with respect to the trapdoor. The beam weighed 36 kg, and that together with his own body weight caused the trapdoor to give way suddenly, and he fell feet first.
2. In the second phase, there was an immediate direct impact to the base of the skull (evident in the trauma to the mastoid and right petrous ridge) produced by the iron beam he was holding on his right shoulder. That beam did not fall through the open trapdoor because of its oblique angle. The direct impact to the base of the skull produced a serious encephalic laceration-contusion, with immediate loss of consciousness. As a result, the worker was unable to cry for help after his fall. To corroborate our reconstruction there weren't highlighted at the the upper limbs and, in particular, of the hands, as it wasn't no try to grab something to avoid the fall from height.
3. In the third phase, the worker, who fell in an upright position, hit one or more sections of the metal tube scaffolding - with cylindrical shape and 240 cm from the ground - located below the trapdoor. He struck the scaffolding with his right knee. That had two results: (a) it slowed the speed of his fall; (b)

through a fulcrum action, his body underwent rotation such that his head was directed toward the floor.

4. In the fourth phase, the worker hit the base of the scaffolding. In particular, the right frontal-zygomatic region hit the iron wheel on the scaffolding, which produced the lacerated, contused wounds described above. The height of the fall was 600 cm.

Particularly, other causes were excluded, on the basis that the fracturative complex at the level of the middle and anterior right cranial fossa, was due to a direct impact of this area against the carried iron beam. In addition, to corroborate our reconstruction at the autopsy there weren't highlighted major injuries to the thoracic and abdominal organs, as well as to the four limbs.

This dynamic reconstruction indicated that there was no liability on the part of the employer. Another company was responsible for the safety of the flooring and movement of industrial installation equipment.

CONCLUSION

This case study shows that a correct, exhaustive approach at the scene of an accident cannot disregard matching circumstantial data, results of the external examination, and necropsy data. Applying forensic medical knowledge at the scene establishes an investigative pathway: it follows the evidence related to the injury rather than constructing a theory for the event and then looking for evidence to support that theory. To ensure a multidisciplinary approach, it is necessary for there to be coherence with all elements from all phases of an investigation (1,3,8). In forensic science, it is very important to assess the quality of medicolegal activities.

CONFLICT OF INTEREST

The authors declare that there is no conflict of interest regarding the publication of this paper.

REFERENCES

1. **Miller T.** Crime scene investigation laboratory manual book. San Diego: Academic Press, 2018.
2. **Giugliano P, Feola A, La Sala F, Buonomo C, Della Pietra B.** A case of suicide by a large number of sharp force injuries. *Medico-Legal Update* 2018; 18(1): 10-12.
3. **Feola A, Di Mizio G, Colucci M, Giordano C, Della Pietra B.** Use of autopsy findings

- in evaluation of evidence collected during crime scene investigation to detect a staging in a case of work-related fatality. *Acta Medica Mediterranea* 2020; 36(3): 1929-1932.
4. **Abder-Rahman H, Jaber MS, Al-Sabaileh SS.** Injuries sustained in falling fatalities in relation to different distances of falls. *J Forensic Legal Med* 2018; 54: 69-73.
 5. **Perotti S, Russo MC.** Work-related fatal injuries in Brescia County (Northern Italy), 1982 to 2015: A forensic analysis. *J Forensic Legal Med* 2018; 58: 122-125.
 6. **Manudhane K, Bartere MM.** Methodology for evidence reconstruction in digital image forensics. *Glob J Comp Scie Technol* 2014; 2,11(2): 1312-1318.
 7. **Buck U, Naether S, Räss B, Jackowski C, Thali MJ.** Accident or homicide–virtual crime scene reconstruction using 3D methods. *Forensic Sci Int* 2013; 225(1–3): 75-84.
 8. **Filetti V, Di Mizio G, Rendine M, et al.** Volatile organic compounds: instrumental and canine detections link an individual to the crime scene. *Egypt J Forensic Sci* 2019; 9: 35.

POKYNY PRO AUTORY

Aktuální pokyny pro autory jsou k dispozici na níže uvedených odkazech:

<http://www.soudnikarstvi.cz/wp-content/uploads/2014/04/3-Pokyny-pro-autory.pdf>

<http://www.soudnikarstvi.cz/wp-content/uploads/2014/04/3-Instructions-for-Authors.pdf>