A fatal case of severe methemoglobinemia presumably due to chlorate ingestion

Kinoshita H.[1], Yoshioka N.[2], Kuse A.[3], Nishiguchi M.[4], Tanaka N.[1], Jamal M.[1], Kumihashi M.[1], Nagasaki Y.[5], Ueno Y.[3], Ameno K.[1]

[1]Department of Forensic Medicine, Faculty of Medicine, Kagawa University, Japan
[2]Public Health Science Research Center, Hyogo Prefectural Institute of Public Health and Consumer Sciences, Japan
[3]Division of Legal Medicine, Department of Environmental Health and Safety, Kobe University Graduate School of Medicine, Japan
[4]Department of Legal Medicine, Hyogo College of Medicine, Japan
[5]Hyogo Medical Examiners Office, Japan

SUMMARY
A fatal case due to severe methemoglobinemia is presented. A male in his forties was found unconscious in his house and, despite intensive care, death was confirmed approximately 11 hours later. Toxicological analysis using ion chromatography revealed the presence of chlorate in the stomach contents. However, chlorate was not detected in the blood, and no other drugs or ethanol were detected in the blood either. We concluded that the cause of death was presumably due to chlorate poisoning, based on the results of the autopsy and the toxicological examination.

Keywords: methemoglobinemia – poisoning – chlorate – ion chromatography

Smrtelný případ těžké methemoglobinemie pravděpodobně v souvislosti s požitím chlorátu

SOUHRN
Je prezentován smrtelný případ v souvislosti s těžkou methemoglobinemií. Muž o svých čtyřicátinách byl nalezen ve svém domě v bezvědomí a přes intenzivní péči byla konstatována smrt o 11 hodin později. Toxikologická analýza s užitím iontové chromatografie odhalila přítomnost chlorátu v žaludečním obsahu. Nicméně chlorát nebyl prokázán v krvi ani jiná droga nebo ethanol. Na základě pitvy a toxikologického vyšetření jsem uzavřeli, že příčinou smrti byla pravděpodobně otrava chlorátem

Klíčová slova: methemoglobinémie – otrava – chlorát – iontová chromatografie

Soud Lek 2011; 56(3): 43–44

Methemoglobin is an oxidized form of hemoglobin (8). The most cause of methemoglobin is ingestion or exposure to an oxidizing agent (10). It oxidizes ferrous iron (Fe^{2+}) to ferric iron (Fe^{3+}) within a hemoglobin molecule, and causes that impairment of O_2 and CO_2 transport leading to tissue or cellular hypoxia (10). Here we report on a case of death by severe methemoglobinemia which was presumably due to the ingestion of chlorate.

CASE HISTORY

A male in his forties (height 173 cm, weight 67 kg) was found unconscious in the bathroom of his house. The deceased had a history of liver dysfunction. Severe methemoglobinemia was diagnosed following admission to the hospital. Despite intensive care, including blood transfusion and methylene blue administration, his death was confirmed approximately 11 hours later.

✉ ***Correspondence address:***
Dr. H. Kinoshita
Department of Forensic Medicine
Faculty of Medicine, Kagawa University,
1750-1, Miki, Kita, Kagawa, 761-0793, Japan
tel.: +81-87-891-2140 fax: +81-87-891-2141
e-mail: kinochin@med.kagawa-u.ac.jp

AUTOPSY FINDINGS

No external evidence of violence was found. The heart weighed 325 g and contained 460 ml of chocolate brown colored blood without coagulum, and the brain weighed 1374 g, neither having any abnormal findings. The left and right lungs weighed 463 and 542 g, respectively, and were severely congested. Histological examination revealed marked congestion and edema of the lungs. The kidneys showed congestion with degradation of the tubules. The stomach contained approximately 300 ml of blueish brown fluid, without food residue. Femoral blood and stomach contents were collected for subsequent toxicological examination and kept at -70 °C until analysis.

A drug screening test using Triage™ (Biosite Diagnostic Inc, San Diego, USA) panel was negative. Quantitation of ethanol was performed using head-space gas-chromatography. The presence of methemoglobin was determined by spectrophotometry, according to the Evelyn and Malloy method (2). Toxicological screening was performed using a high performance liquid chromatography drug analysis system (Class-VP system, Shimadzu, Kyoto, Japan) (4). The operation of this system was in accordance with the manufacturer's specifications.

The ion chromatography is equipped for the screening of anions, since the high concentration of methemoglobin was detected. The ion chromatography system, consisted of a pump LC-10AD and column oven CTO-10A, equipped with a conductivity detector CDD-6A (Shimadzu, Kyoto, Japan) was used. Analysis was carried out using a Shin-Pak IC-A3 column (4.6mm i.d. X 150 mm, Shimadzu, Kyoto, Japan), at 40 °C. The flow rate of the mobile phase (8 mM p-Hydroxybenzoic acid /3.2 mM Bis(2-hydroxyethyl) iminotris(hydroxymethyl)methane /50 mM Boric acid) was 1.2 ml/min. The blood and the stomach contents were subjected to toxicological analysis. Sample preparation was as follows; Samples (0.1 ml) were diluted with distilled water (1:19). Following centrifugation, liquid-solid extraction using SepPak light C_{18} (Waters, Milford, USA) was performed. The 10 µl of the eluent was injected into the ion chromatography.

RESULTS AND DISCUSSION

The concentrations of methemoglobin in postmortem blood was 60.1 %. No ethanol or other drugs were detected in blood. As the normal methemoglobin level is less than 1 % in healthy subjects, this levels of methemoglobinemia cause severe cyanosis and symptoms such as dyspnea, headache, seizure and coma (8,10). As the most common cause of acquired methemoglobinemia is exposure to an oxidizing agent, such as nitrates, nitrites or chlorate (3,7,8,10), we performed an additional examination using ion chromatography.

Figure 1 (a) shows the chromatogram of stomach contents by ion chromatography. Chlorate ion (153.7 µg/ml) was detected in the stomach contents, but not in the blood sample. It would be difficult to detect in blood sample, as described previously (8,9). Although the metabolism of chlorate is not well understood, it is probably reduced to chlorite and then to chloride (3). In the present case, we were able to detect the presence of chlorate in the stomach contents, which provided supportive diagnostic evidence of chlorate intake (1,3). This also emphasizes the importance of chemical analysis of stomach contents (5,6), especially in case of ingestion of unstable substances such as chlorate or hypochlorite (3,5). From the results of the toxicological examination and autopsy finding, we conclude that the cause of death was severe methemoglobinemia presumably due to chlorate poisoning.

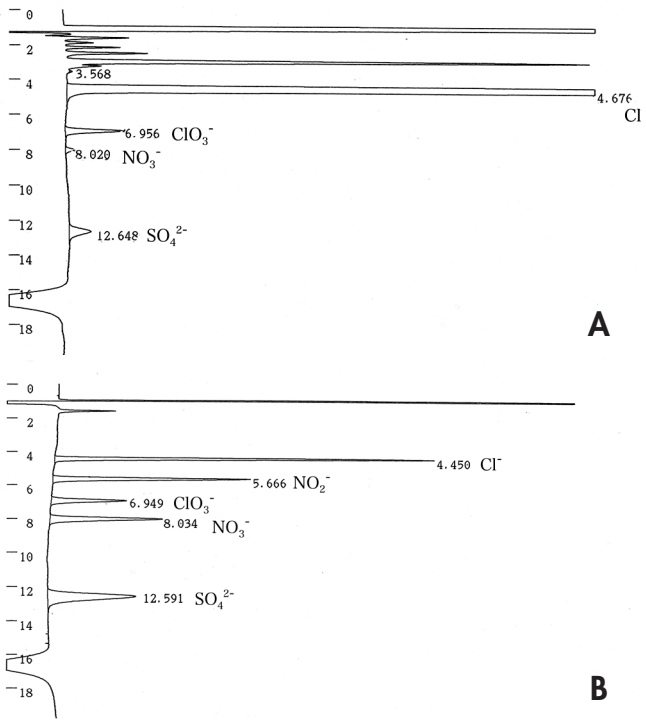

Figure 1: Ion chromatogram of stomach contents (**A**) and standard solution of chloride, chlorate, nitrate, nitrite and sulfate ion (10 µg/ml each) (**B**).

REFERENCES

1. **Blakley BR, Fraser LM, Waldner C.** Chlorate poisoning in beef cattle. *Can Vet J* 2007; 48: 1071–1073.
2. **Evelyn KA, Malloy HT.** Microdetermination of oxyhemoglobin, methemoglobin and sulfhemoglobin in a single sample of blood. *J Biol Chem* 1938; 126: 665–662.
3. **Eysseric H, Vincent F, Peoc'h M, Marka C, Aitken Y, Barret L.** A fatal case of chlorate poisoning: confirmation by ion chromatography of body fluid. *J Forensic Sci* 2000; 45: 474–477.
4. **Kinoshita H, Taniguchi T, Kubota A, et al.** An autopsy case of imipramine poisoning. *Am J Forensic Med Pathol* 2005; 26: 271–274.
5. **Kinoshita H, Fuke C, Kasuda S, et al.** Evidence of hypochlorite ingestion: an autopsy case. *Res Pract Forens Med* 2007; 50: 193–198.
6. **Moriya F, Takahashi N, Hashimoto Y.** A case of acute asphyxial death of a child in which toxicologic analysis of the stomach contents was significant. *Res Pract Forens Med* 2001; 44: 177–181.
7. **Saito T, Takeichi S, Osawa M, Yukawa N, Huang X-L.** A case of fatal methemoglobinemia of unknown origin but presumably due to ingestion of nitrate. *Int J Legal Med* 2000; 113: 164–167.
8. **Sands TR.** Chlorates. *In:* **Olson KR**, ed. Poisoning & drug overdose (5th ed) New York: Lange Medical Books/McGraw-Hill; 2007: 159–160.
9. **Steffen C, Seitz R.** Severe Chlorate poisoning: report of a case. *Arch Toxicol* 1981; 48: 281–288.
10. **Wright RO, Lewander WJ, Woolf AD.** Methemoglobinemia: etiology, pharmacology, and clinical management. *Ann Emerg Med* 1999; 34: 646–656.